

Four Common Anatomic Variants that Predispose to Unfavorable Rhinoplasty Results: A Study Based on 150 Consecutive Secondary Rhinoplasties

Mark B. Constantian, M.D.

Nashua, N.H.

A retrospective study was conducted of 150 consecutive secondary rhinoplasty patients operated on by the author before February of 1999, to test the hypothesis that four anatomic variants (low radix/low dorsum, narrow middle vault, inadequate tip projection, and alar cartilage malposition) strongly predispose to unfavorable rhinoplasty results. The incidences of each variant were compared with those in 50 consecutive primary rhinoplasty patients. Photographs before any surgery were available in 61 percent of the secondary patients; diagnosis in the remaining individuals was made from operative reports, physical diagnosis, or patient history. Low radix/low dorsum was present in 93 percent of the secondary patients and 32 percent of the primary patients; narrow middle vault was present in 87 percent of the secondary patients and 38 percent of the primary patients; inadequate tip projection was present in 80 percent of the secondary patients and 31 percent of the primary patients; and alar cartilage malposition was present in 42 percent of the secondary patients and 18 percent of the primary patients. In the 150-patient secondary group, the most common combination was the triad of low radix, narrow middle vault, and inadequate tip projection (40 percent of patients). The second largest group (27 percent) had shared all four anatomic points before their primary rhinoplasties. Seventy-eight percent of the secondary patients had three or all four anatomic variants in some combination; each secondary patient had at least one of the four traits; 99 percent had two or more. Seventy-eight percent of the primary patients had at least two variants, and 58 percent had three or more. Twenty-two percent of the primary patients had none of the variants and therefore would presumably not be predisposed to unfavorable results following traditional reduction rhinoplasty.

This study supports the contention that four common anatomic variants, if unrecognized, are strongly associated with unfavorable results following primary rhinoplasty. It is important for all surgeons performing rhinoplasty to recognize these anatomic variants to avoid the unsatisfactory functional and aesthetic sequelae that they may pro-

duce by making their correction a deliberate part of each preoperative surgical plan. (*Plast. Reconstr. Surg.* 105: 316, 2000.)

It is virtually axiomatic that rhinoplasty ranks among the most difficult plastic surgical operations. Even without adding grafts or the necessity of correcting airway problems, classic reduction rhinoplasty, conceptually simple as it may seem, frequently produces results that disappoint both patient and surgeon. It has been my contention for several years that rhinoplasty is difficult, in part, because the model under which it is conceived and performed is insufficiently complex; that model relies on two assumptions that may not be (and frequently are not) true.¹

The first of these assumptions is that the nasal soft-tissue cover has the infinite ability to contract to any reduced skeletal framework. If this assumption were always true, however, supratip deformity would never occur and augmentation would not correct it.^{2,3}

The second assumption is that each nasal region functions independently, so that surgical changes made in one anatomic area affect no other areas. Accordingly, reduction of the nasal dorsum should create changes in dorsal contour only. It is the belief in this principle that directs surgeons to plan the correction of a convex nasal dorsum by imagining a straight line from the nasal root to the ideal point of

From the Departments of Surgery (Plastic Surgery) at St. Joseph Hospital and Southern New Hampshire Medical Center, and Dartmouth Medical School. Received for publication August 9, 1999; revised September 3, 1999.

Presented at the Annual Meeting of the American Society for Aesthetic Plastic Surgery, in Dallas, Texas, May 17, 1999.

greatest tip projection, with the expectation of creating a straight dorsum by resecting the skeletal framework that lies anterior to that line.⁴

Dorsal resection, however, is one of the most powerful examples of the fact that the second assumption is incorrect and that many nasal regions function interdependently, not independently: Dorsal reduction not only changes bridge contour, but may also alter real and apparent bony vault width, middle vault (and therefore internal valvular) support, nasal length, nostril contour, real and apparent columellar position, and apparent nasal base size.⁵⁻¹⁰ Similarly, changes in alar cartilage volume or position may affect not only tip support but also nasal length, nasal base size, nostril and alar rim support and contour, and the competence of the airway at the external nasal valves.^{5,11-13} It is exactly these types of complexities, based on the two assumptions listed above, that account in part for the frustration that many surgeons experience in trying to achieve their preoperative goals.

It should not be surprising, then, that variations in preoperative nasal anatomy may either complicate or simplify any surgical plan, and that certain anatomic traits may place the patient at particular risk for an unsatisfactory postoperative result.^{12,14-19} The current nature of my surgical practice provides the opportunity to assess and advise approximately 200 patients each year who have undergone prior unsuccessful rhinoplasties. A review of 150 consecutive patients on whom I have performed secondary rhinoplasty supports the conclusion that four common anatomic variants (low radix or low dorsum,^{5,8,15} narrow middle vault,^{4,20,21} inadequate tip projection,^{16,22} and cephalic malposition of the alar cartilage lateral crura^{11,12,17-19,23}) frequently precede an unsatisfactory rhinoplasty result. The purpose of this article is to delineate the incidence and surgical relevance of these four anatomic variants based on a retrospective study of 150 consecutive secondary and 50 consecutive primary rhinoplasty patients.

PATIENTS AND METHODS

Patient Population

One hundred fifty consecutive secondary rhinoplasty patients (104 women, 46 men) and 50 consecutive primary rhinoplasty patients (36 women, 14 men) whom I operated on

before February of 1999 comprise the populations studied. The secondary patients had undergone a mean of 2.9 (range, 1 to 9) prior rhinoplasties. The hypothesis being tested was that the secondary patients would share one or more of four anatomic traits defined below. Photographs before any surgery were available for 61 percent of the secondary patients (92 patients); in the remaining individuals, diagnosis was made from operative reports, physical diagnosis, or patient history.

Definition of Anatomic Traits

The anatomic characteristics being tabulated were defined as follows: The *low radix* or *low dorsum* (Fig. 1) began caudal to the level of the upper lash margin with the patient's eyes in primary gaze. The *narrow middle vault* (Figs. 2 and 3) defined any upper cartilaginous vault that was at least 25 percent narrower than either the upper or lower nasal thirds. *Inadequate tip projection* (Fig. 4) defined any tip that did not project to the level of the anterior septal angle. *Alar cartilage cephalic malposition* (Fig. 5) defined any lateral crura rotated 45 degrees or more to the plane of the alar rims.^{12,23}

Surgical Techniques

All rhinoplasties were performed endonasally. Inferior turbinectomy was not done. I use Sheen and Sheen's methods with very few modifications.^{24,25} Only autogenous materials were used for the reconstructions, although Gore-Tex (Gore-Tex 1 mm SAM facial implant, a brand of expanded polytetrafluorethylene, W. L. Gore Associates, Flagstaff, Ariz.) provided maxillary augmentation in some cases.

Rhinomanometric Measurements

Geometric mean nasal airflow was measured for each patient preoperatively and at postoperative intervals as previously documented,^{11,12,23} using anterior, mask rhinomanometry in airways decongested by topical 1% phenylephrine hydrochloride to minimize the effects of mucosal factors and nasal cycling. Independent measurements were made of the volume of air inspired through each airway during a standard 14-sec test period; geometric mean nasal airflow was calculated as the square root of the product of the air volumes inspired through each nasal passage. The development and rationale of this protocol have been described previously.^{11,12,23}

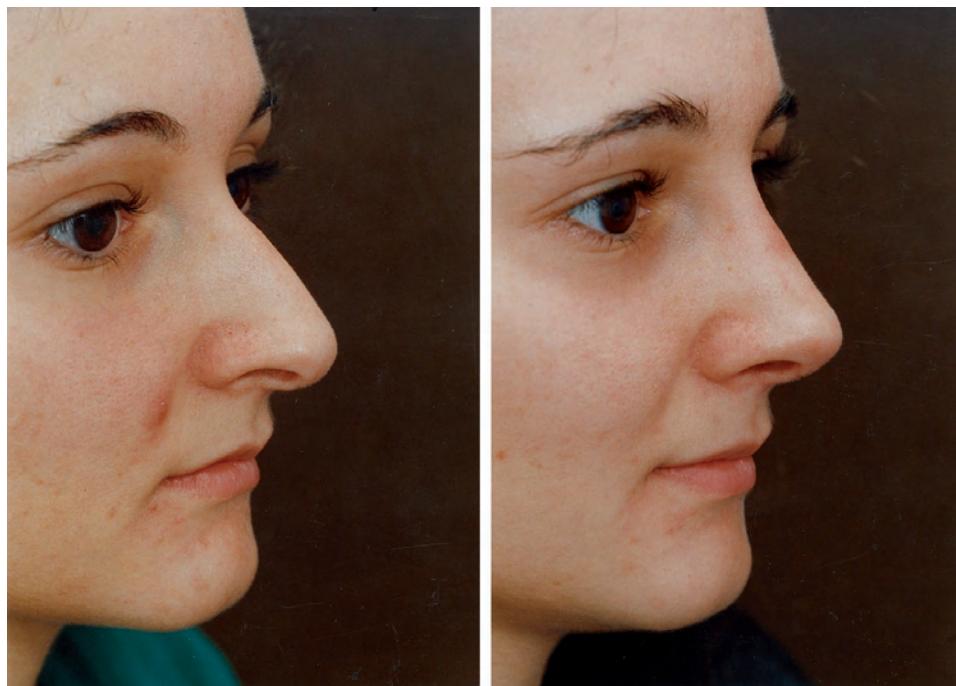

FIG. 1. Low radix (primary rhinoplasty patient). (*Left*) Preoperative view. (*Right*) One-year postoperative oblique view following dorsal resection and radix, spreader, and tip grafts demonstrates the apparent decrease in nasal base size caused by elevation of the nasal root, despite an actual increase in base size from tip grafting.

RESULTS

The incidences of each of the anatomic traits assessed for the secondary rhinoplasty patients in this study are presented as they occurred in isolation (Table I) and in various combinations (Table II). The results of the primary rhinoplasty group are presented in Tables III and IV.

The most common preoperative anatomic trait was the low radix or low dorsum, which had been present preoperatively in 93 percent of the secondary rhinoplasty patients and 32 percent of the primary patients (Figs. 1 and 6 through 10). The narrow middle vault had been present preoperatively in 87 percent of our secondary patients and 38 percent of primary patients (Figs. 2, 3, 8, and 9). Eighty percent of the secondary patients in this consecutive series had inadequate tip projection before they underwent their first rhinoplasties (compared with 31 percent of the primary patients) (Figs. 4 and 7); 42 percent of our patients originally had cephalic malposition of the alar cartilage lateral crura (compared with 18 percent of the primary patients) (Figs. 5, 7 and 8).

The anatomic traits occurred in various similar groupings in both populations (Tables III and IV). The most common combination

among the secondary rhinoplasty patients was the triad of low radix or low dorsum, narrow middle vault, and inadequate tip projection, shared by 40 percent (Fig. 6), and also present in 28 percent of our primary patients (Fig. 1). The second largest secondary patient group (27 percent) had all four anatomic points preoperatively (Fig. 8); these traits occurred in 28 percent of the primary group. Other combinations occurred with less frequency, with the result that 78 percent of our secondary patients had either three or all four traits in some combination. Each secondary patient had at least one of the four traits, and 99 percent had at least two. Interestingly, thick skin, which is traditionally assumed to be one of the chief anatomic characteristics that lead to an unfavorable rhinoplasty result, was present in only 31 percent of the secondary patients.

Among the primary rhinoplasty patients, 58 percent had three or more traits, 78 percent had two or more, and 22 percent had none of these four anatomic variants.

DISCUSSION

The reader might reasonably wonder at this point what the presented data prove. After all, one finds only what one is seeking. If the pa-

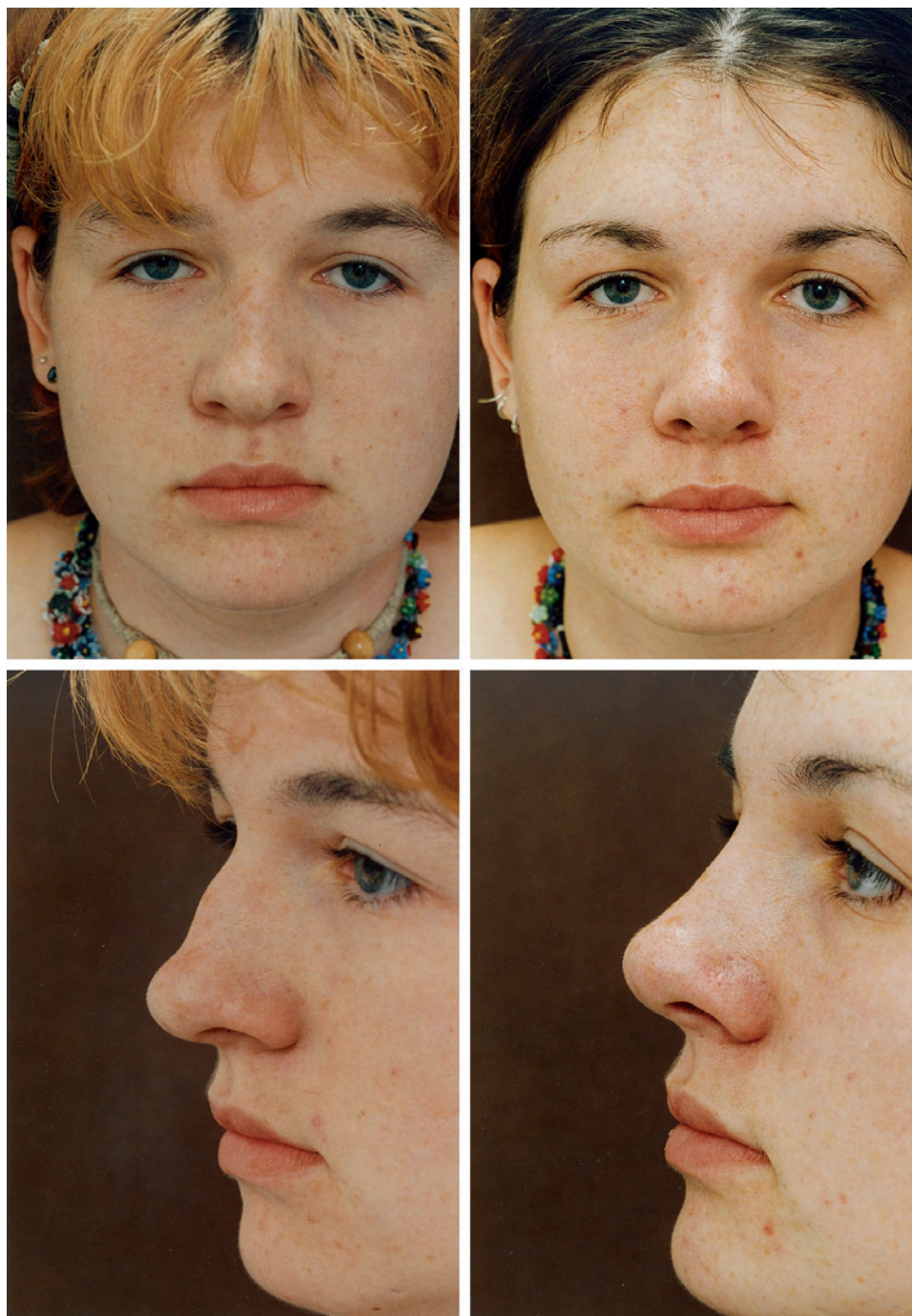

FIG. 2. Narrow middle vault, primary patient. The patient was corrected with dorsal resection, spreader, and long dorsal grafts; airflow increased 2.5 times over preoperative values. (*Left*) Preoperative views; (*right*) 14-month postoperative views.

tients' preoperative photographs had been searched for boxy tips, acute nasolabial angles, or high septal deviations, would these not have been identified also? No matter what the preoperative deformity, it could be argued, some surgeons will fail in its correction, and some patients yield unacceptable results despite adequate operations. Why should recognition of

these four anatomic entities be so critical to success in rhinoplasty?

There is some merit in those criticisms. Epidemiologically, ours is a retrospective study that began with patients undergoing secondary rhinoplasty, from which vantage point their clinical courses were retraced, seeking possible associations between the patients' unfavorable

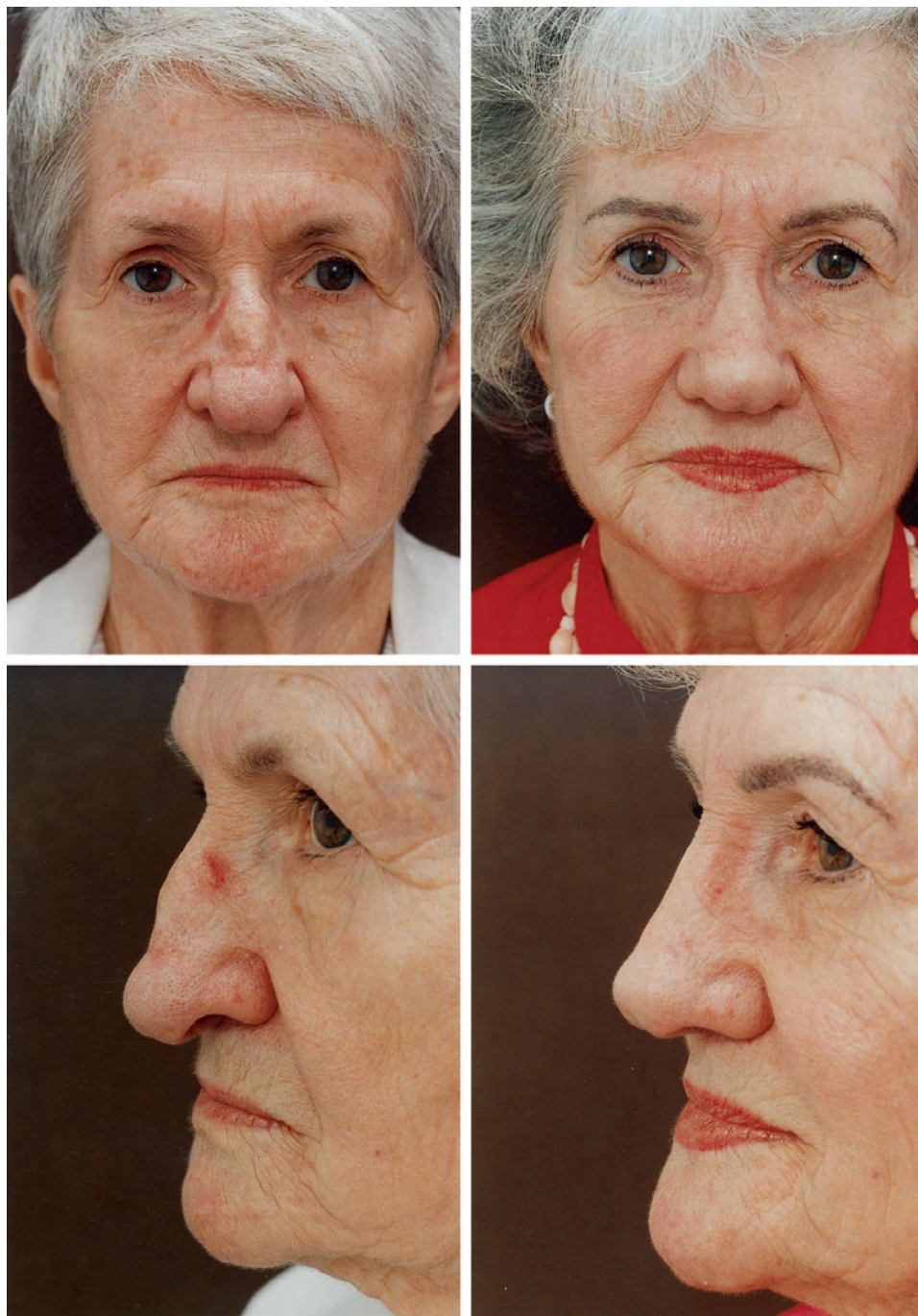

FIG. 3. (*Left*) Preoperative views of a secondary rhinoplasty patient who had undergone a septal resection with loss of nasal base support. (*Right*) At 1 year postoperatively, caudal support grafts,⁶¹ not struts, elevate the nasal base; spreader and dorsal grafts were also placed.

outcomes and certain anatomic traits that were believed to have preceded them. Have we found only what we were seeking?

Other anatomic characteristics (e.g., alar distortion, a “too short” nose, a “too narrow” tip, an excessively high postoperative bridge, poor tip contour, nasal asymmetry) were solicited and tab-

ulated, and our patients’ preoperative photographs were examined for other individual or grouped anatomic traits that might suggest particular “traps” for the operating surgeon. Certainly many anatomic features may make any rhinoplasty particularly difficult, and their corrections have been described by

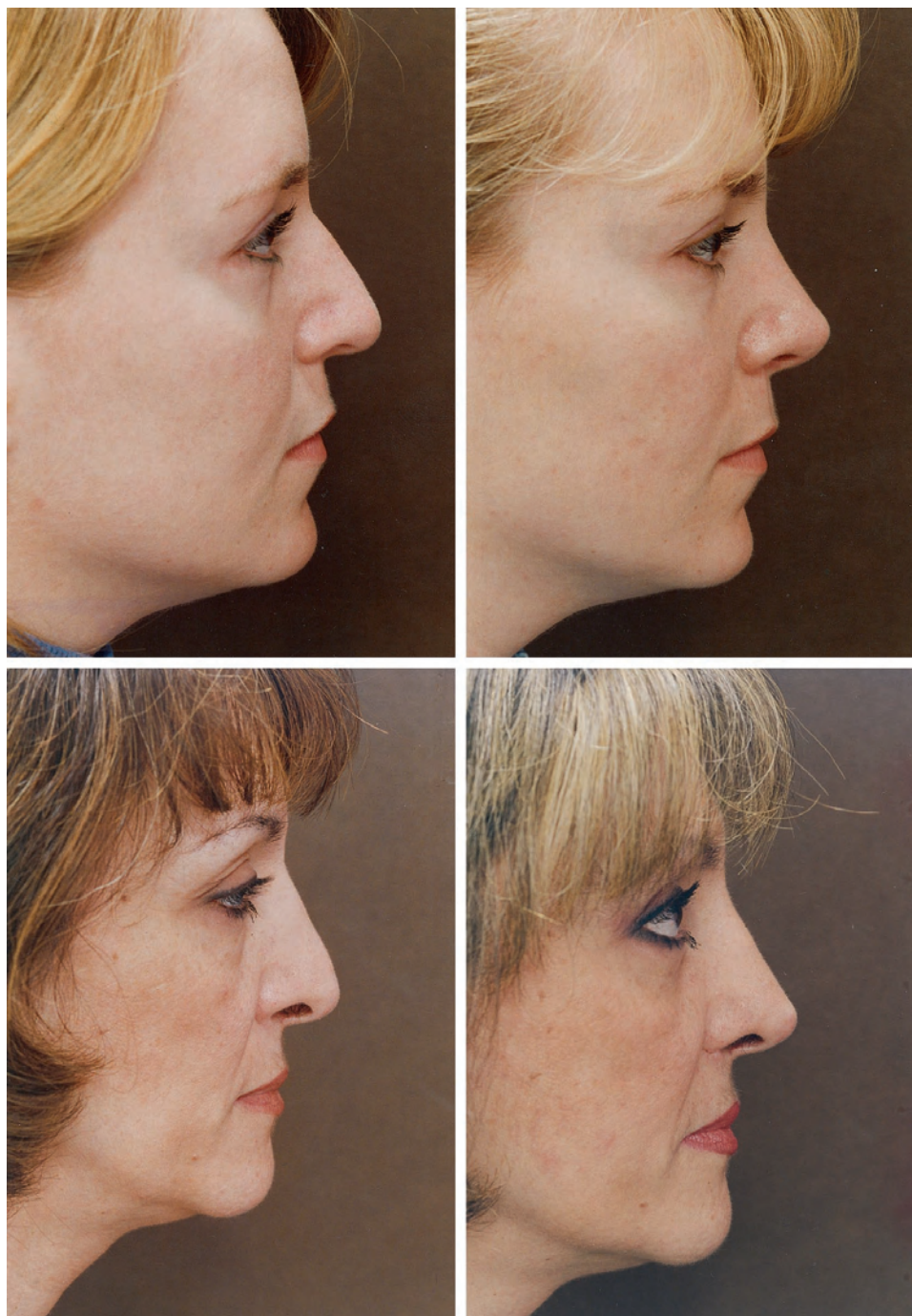

FIG. 4. Inadequate tip projection (primary and secondary patients). The tip lobules appear to "hang" from the septal angles. Both the primary patient (*above*, preoperatively and 1 year postoperatively) and the secondary patient (*below*, preoperatively and 15 months postoperatively) underwent tip grafting, which has elevated the tip lobules anterior to the septal angles. Radix grafts were also placed.

a number of authors.²⁶⁻⁴¹ Although such associations were not found, the hypothesis that provoked the study was that the same small group of preoperative nasal characteristics had occurred with unusual frequency in the secondary rhinoplasty patients who presented to

me, and that it was therefore these four entities, alone or in combination, that created particular hazards for the surgeon who had not diagnosed them preoperatively. Each of these four traits inherently impairs or defeats the surgeon's ability

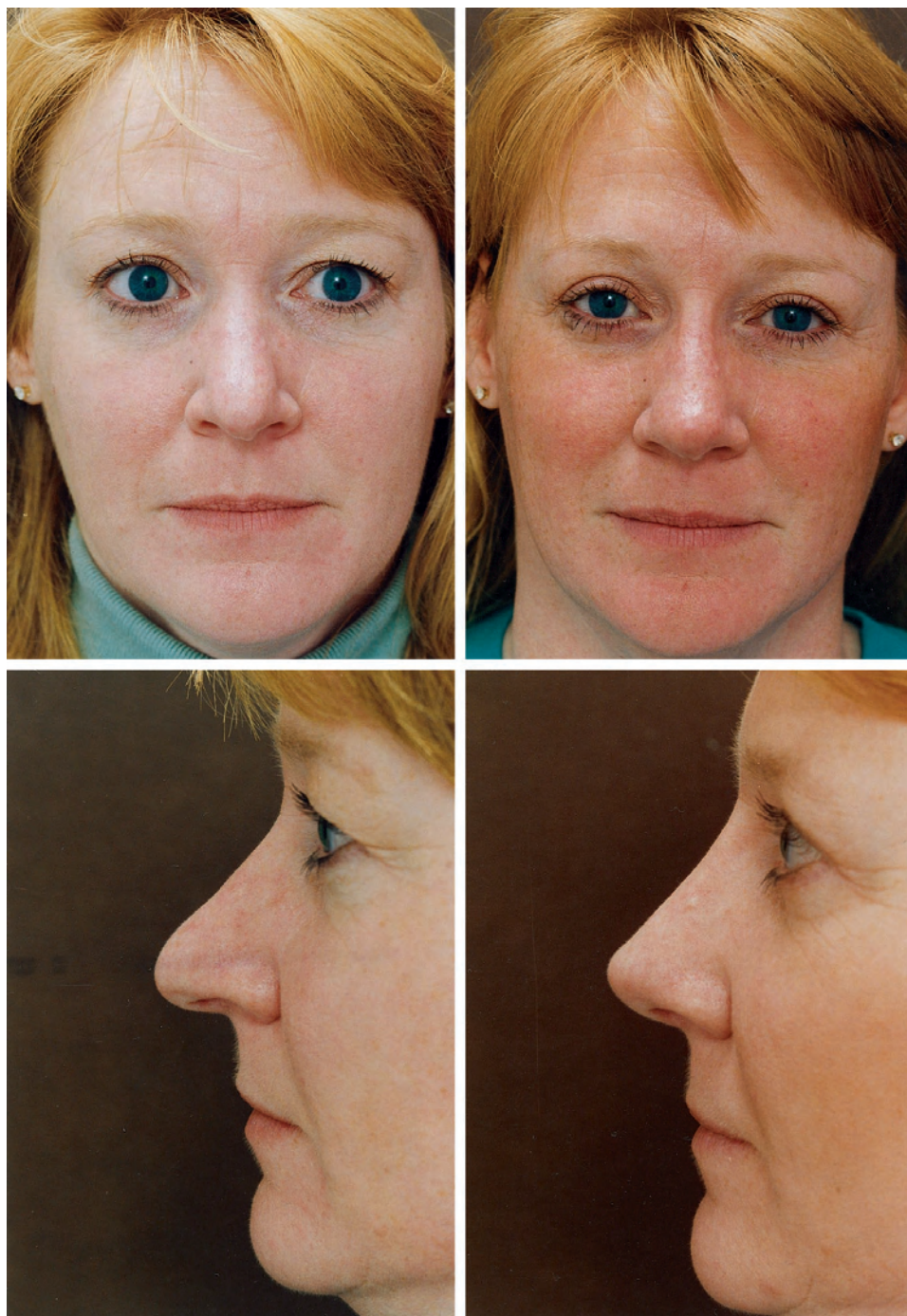


FIG. 5. Primary rhinoplasty patient with alar cartilage malposition (*Left*) Preoperative views; (*right*) 18-month postoperative views following dorsal, spreader, and tip grafts and relocation of the alar cartilage lateral crura to support the external valves.

to create even the most routine rhinoplasty goal: a straight bridge and an optimal airway.

Low Radix or Low Dorsum

The low radix/low dorsum has been identified by Sheen and others^{7,8,9,15} as one of several primary causes of nasal imbalance: an upper nose that seems too small for its lower nasal

component. This anatomic variant was present preoperatively in 93 percent of our secondary patients. The classic imbalance may take the form of a depression or notch in the upper nasal third (low radix),¹⁵ or an entire (usually straight) dorsum that is low relative to the size of the lower nasal third (nasal base).^{4,8-10} Whether or not the patient has a dorsal con-

TABLE I
Incidence of Preoperative Anatomic Traits in 150
Consecutive Secondary Rhinoplasty Patients

Anatomic Trait	Percent of Patients
Low radix or dorsum	93
Narrow middle vault	87
Inadequate tip projection	80
Alar cartilage malposition	42

vexity, the surgeon often hears the same preoperative complaint: "The tip of my nose sticks out too far." If the surgeon chooses to reduce the nasal dorsum for any reason, the patient's preoperative skeletal imbalance and skin sleeve maldistribution (i.e., too much skin in the lower nose) worsen. The lower nose now appears even larger.¹⁰ A subsequent resection of alar base components (caudal septum, alar cartilages, nostrils) to recreate appropriate proportions will exaggerate the imbalance. Because nasal base topography is so complex, because refined nasal tip contours are desired by most rhinoplasty patients, and because the lower nasal soft tissues have the least ability to conform to reduced skeletal structures, the low radix or low dorsum creates a technical dilemma that reduction rhinoplasty worsens. Furthermore, there are constraints on the surgeon's desire to "make a nose that fits the face": whether the patient in Figure 1 is 5'2" or 5'11" tall, her preoperative skin sleeve volume, distribution, and contractility will ultimately restrict the extent to which the surgeon may reduce nasal volume without causing surface distortion or airway obstruction.⁷⁻⁹ Fortunately, there are other choices: either limit tip reduction or raise the dorsum segmentally (Figs. 1, 7, 8, and 10) or entirely (Figs. 2, 5, and 6).^{7-10,42}

TABLE II
Association Incidences of Preoperative Anatomic Traits in
150 Consecutive Secondary Rhinoplasty Patients

Anatomic Traits	Percent of Patients
Low radix/narrow MV/TIP	40
Low radix/narrow MV/TIP/malp	27
Low radix/TIP	8
Low radix/narrow MV	7
Low radix/narrow MV/malp	7
Low radix/TIP/malp	4
Narrow MV/malp	4
Narrow MV	2
TIP	1

MV, middle vault; TIP, inadequate tip projection; malp, alar cartilage malposition.

TABLE III
Incidence of Preoperative Anatomic Traits in 50
Consecutive Primary Rhinoplasty Patients

Anatomic Trait	Percent of Patients
Low radix or dorsum	32
Narrow middle vault	38
Inadequate tip projection	31
Alar cartilage malposition	18

Variations of the latter option are often more predictable (particularly in the secondary patient) because they require less contraction of the thicker nasal base tissues.

Narrow Middle Vault

The narrow middle vault, present preoperatively in 87 percent of our secondary patients, was originally described by Sheen in conjunction with short nasal bones,⁴³ but subsequently has been discussed by that author and others^{20,21,26,44-47} as a nasal configuration that places the patient at special risk for internal valvular obstruction, which may exist preoperatively or may be produced by dorsal resection.^{19,21,26,43,45,46} Although descriptions of valvular collapse had appeared earlier in the rhinoplasty literature,⁴⁸⁻⁵⁰ the missing puzzle piece had been the link between resection of the cartilaginous roof and postoperative internal valvular collapse, a phenomenon recognized by other authors but erroneously attributed to surgical or traumatic avulsion of the upper lateral cartilages from the nasal bones. The width and stability of the upper cartilaginous vault depends not only on bony vault width but also on the height and width of the cartilaginous roof.^{21,26} Resection of even 2 mm of that roof during hump removal ablates the stabilizing confluence that braces the upper lateral cartilages,⁴⁶ which can now fall medially toward the anterior septal edge, restricting airflow at the internal valves and producing a characteristic "in-

TABLE IV
Association Incidences of Preoperative Anatomic Traits in
50 Consecutive Primary Rhinoplasty Patients

Anatomic Traits	Percent of Patients
Low radix/narrow MV/TIP	28
Low radix/narrow MV/TIP/malp	28
Low radix/narrow MV	10
Narrow MV/TIP	8
Narrow MV/malp	2
Low radix/narrow MV/malp	2

MV, middle vault; TIP, inadequate tip projection; malp, alar cartilage malposition.

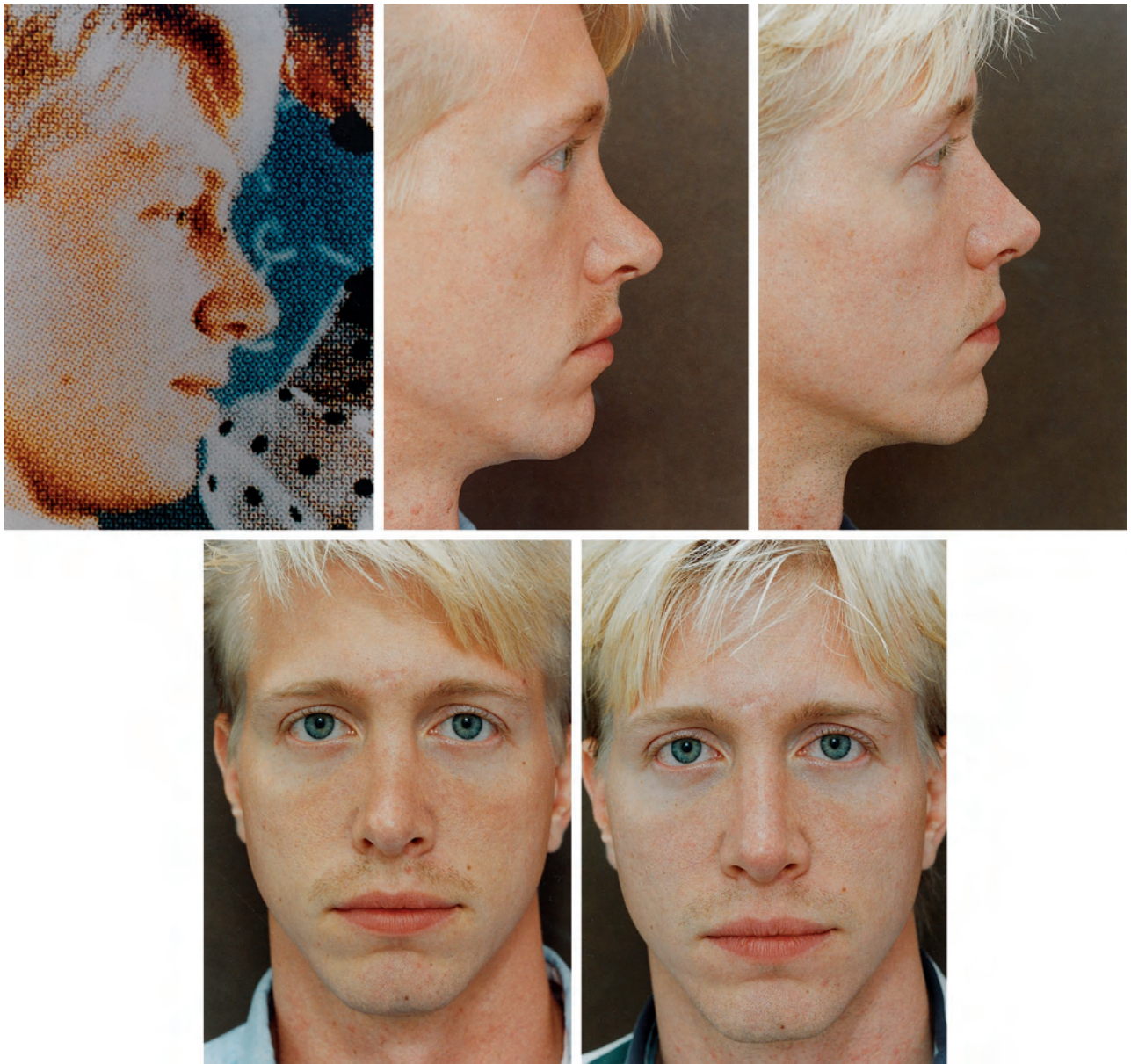

FIG. 6. (Above, left) Patient with low dorsum unrecognized before the primary rhinoplasty. Preoperative secondary views (above, center, and below, left) demonstrate the protean effects of dorsal reduction: an increase in apparent nasal base size, nasal shortening, middle vault collapse. Twelve-month postoperative views (above, right, and below, right) following calvarial bone dorsal and septal cartilage tip grafts. Like spreader grafts, substantial dorsal grafts laterally distract the middle vault and therefore improve internal valvular competence.

verted V" deformity. A visible discontinuity (Figs. 2, 3, 6, 8, and 9) may or may not be obvious, depending on overlying soft-tissue thickness. Our rhinomanometric studies, now comprising a prospective series of 304 consecutive patients with airway obstruction [mean follow-up, 12.8 months; 130 patients followed for more than 12 months (mean follow-up, 24.3 months)], continue to indicate that valvular obstruction was four times more common than pure septal obstruction in our primary rhinoplasty patients

(and 12 times more common in the secondary patients).⁵¹ Reconstruction of incompetent internal valves by substantial dorsal or spreader grafts doubles nasal airflow in most patients²⁶; a recent review of our long-term patients suggest that dorsal and spreader grafts may be even more effective in primary than in secondary patients (3.96 times versus 2.83 times preoperative flow), as might be expected.⁵¹ The narrow middle vault should be recognized preoperatively (particularly if a dorsal resection is planned) and its correc-

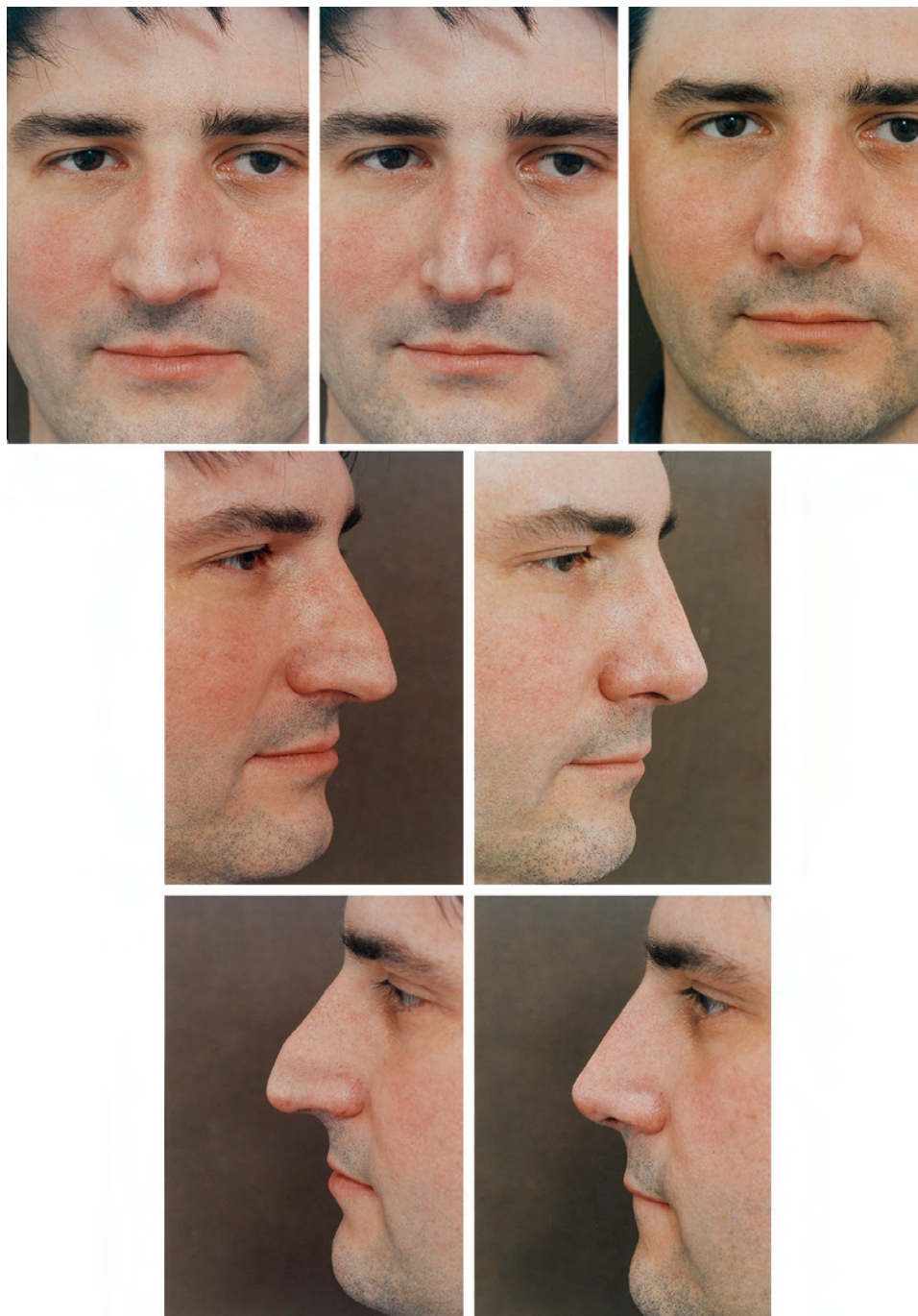
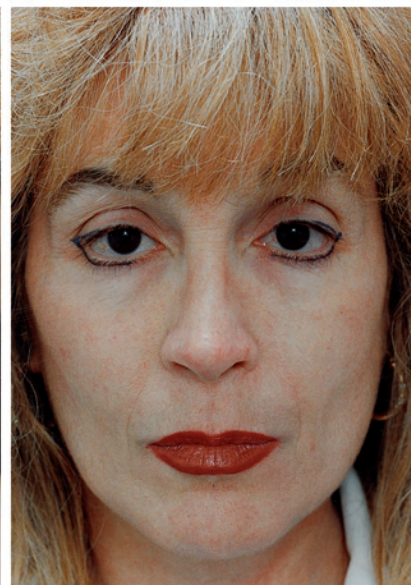
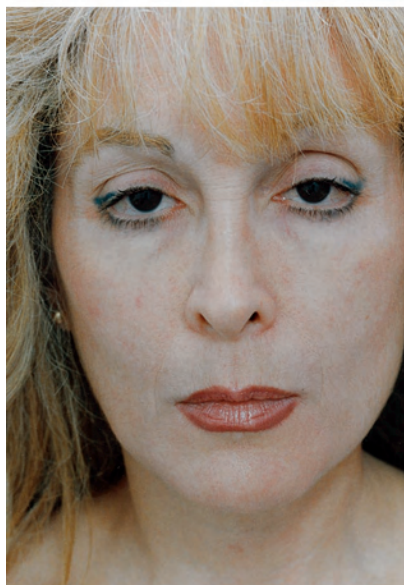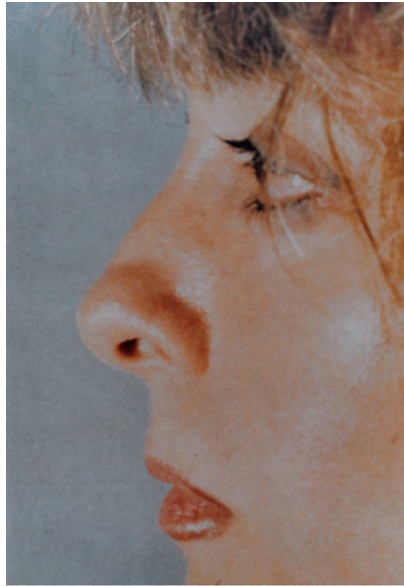FIG. 7. Primary rhinoplasty patient with all four anatomic variants, including alar cartilage malposition: the medial edges of the lateral crura parallel the anterior septal edge. Reconstruction consisted of resection and relocation of the lateral crura; reduction of the cartilaginous dorsum; and septal cartilage dorsal, spreader, and tip grafts. Despite thick, noncontractile skin, the nasal base appears smaller because postoperative nasal length (from radix to tip) is greater. Soft-tissue "memory" prohibits a narrower tip lobule in this heavy skin. (*Above, left and center*) Preoperative frontal views during quiet and forced inspiration. There is incompetence of the internal and external nasal valves. (*Center, left, and below, left*) Preoperative oblique and lateral views. (*Above, right; center, right; and below, right*) One-year postoperative views.

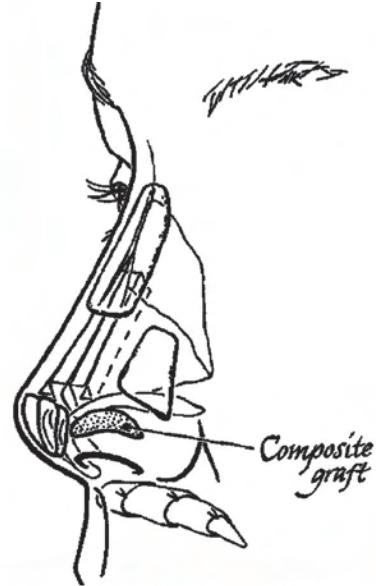

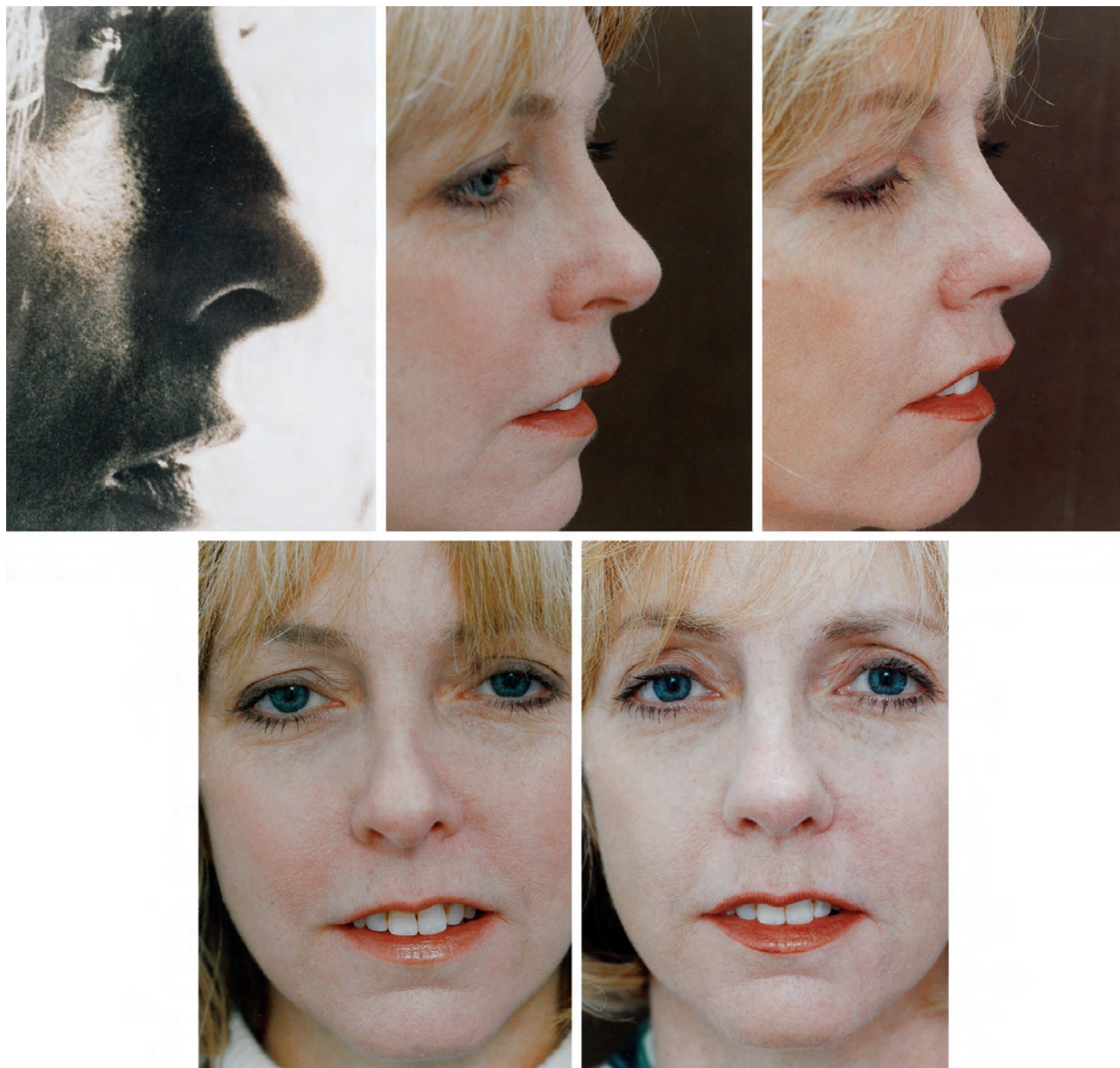


FIG. 9. (Above, left) Patient with low radix, narrow middle vault, and tip lobule that projects only to the septal angle; view before primary rhinoplasty. Although the dorsal convexity is lower, note the similarity to the patient shown in Figure 10. (Above, center, and below, left) Eighteen-month postoperative views following dorsal, spreader, alar wall, and tip grafts. Mean nasal airflow has increased 28 times from re-creation of valvular competence. Frontal and oblique views confirm the confluence of the upper, middle, and lower nasal thirds. (Above, right, and below, right) Dorsal and tip reduction during primary rhinoplasty has collapsed the middle vault and produced supratip deformity.

tion incorporated into the surgical plan. Moreover, the surgeon should consider placing spreader grafts to support internal valves that will

be rendered incompetent by hump removal to avoid creating an airway obstruction that did not exist preoperatively^{21,26,43-45} (Fig. 7).

Fig. 8. Secondary rhinoplasty patient with preexisting low radix, narrow middle vault, and alar cartilage malposition. (Above, left) View before primary rhinoplasty. The lateral crura diverge from the alar rims at 60-degree angles. (Above, right) Schematic of the surgical plan. (Center, left, and below, left) Preoperative views. (Center, right, and below, right) Postoperative views after maxillary augmentation; ear cartilage composite grafts to support the external valves and correct alar notching; and spreader, dorsal, lateral wall, and tip grafts of conchal cartilage. No septal cartilage was available. Ear cartilage was split tangentially and crushed²⁵ for use as a thin, single dorsal graft; this solution is a compromise that should be decided with the patient, because visible or distorted graft edges may appear postoperatively.

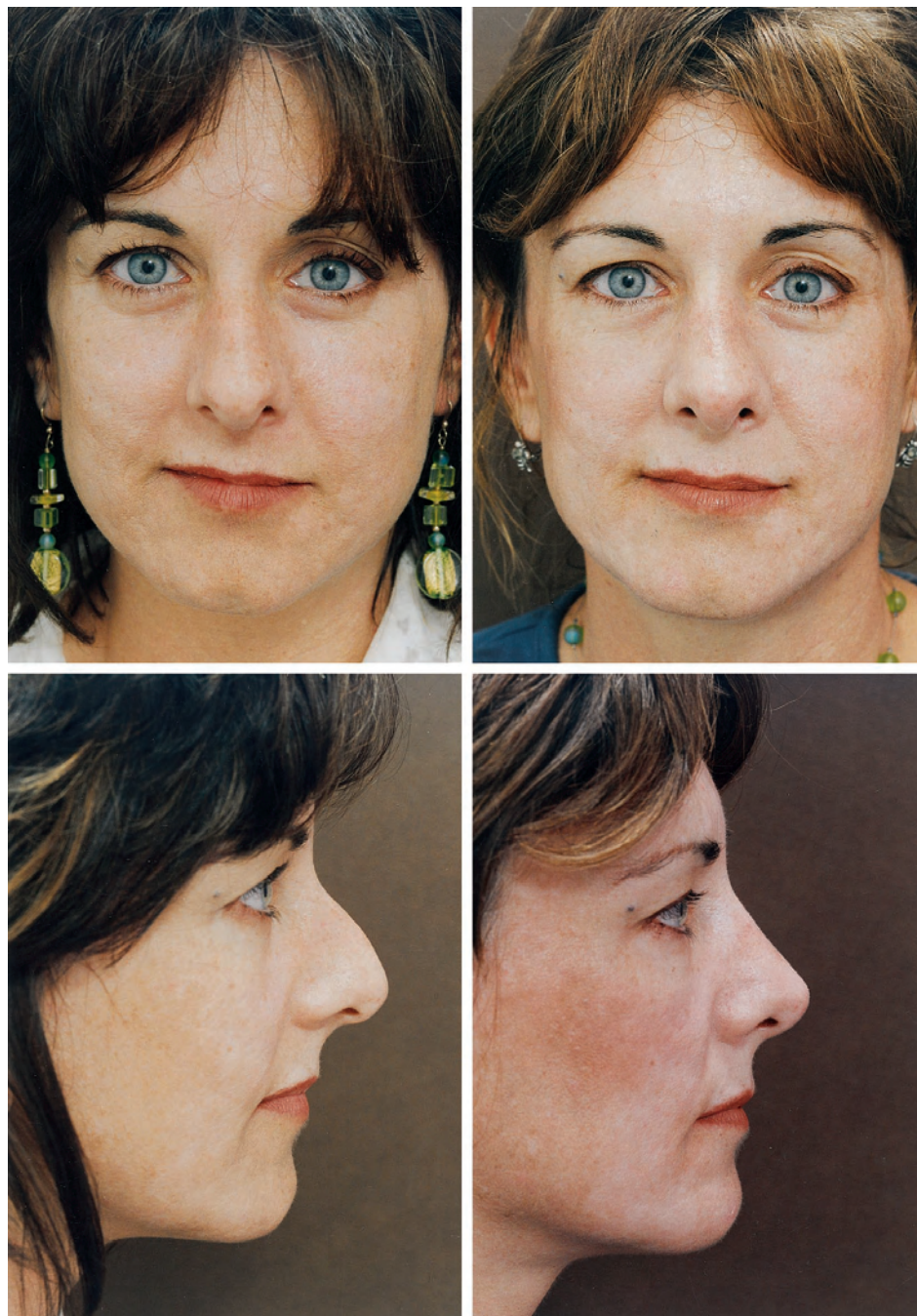

FIG. 10. Primary patient illustrating the preoperative combination that had been present in 40 percent of my secondary patients: the triad of low radix, narrow middle vault (which in this case will be *created intraoperatively* by resection of the broad cartilaginous roof), and inadequate tip projection. Treatment consisted of dorsal reduction and septal cartilage, radix, spreader, and tip grafts. (*Left*) Preoperative views; (*right*) 15-month postoperative views.

Inadequate Tip Projection

Despite its common usage, the term “tip projection” has been used to connote different things by different authors. Some surgeons assess tip projection by measuring the distance of the most projecting point of the tip from some facial parameter (vertical facial plane, nasion, subna-

sale, or alar crease)⁵²⁻⁵⁴; by the relative proportions of the nasal base segments anterior and posterior to the upper lip^{55,56}; or by the relative lengths of the nasal base and the upper lip.⁵⁷

Despite the utility of these definitions in many cases, there are patients whose nasal bases are large but whose tip cartilages are

nevertheless poorly projecting (Figs. 4 and 7). In these individuals, tip projection may be assessed inaccurately as "adequate" by the relative distribution of nasal base skin even though the alar cartilages lack the substance required to create a straight bridge line.⁵⁸

The surgeon may alternatively define tip projection *by the relationship of the tip lobule to the anterior septal angle*: alar cartilages strong enough to support the tip to the level of the septal angle are "adequately projecting" (Figs. 2, 3, 8, *above, left*, and 9, *above, left*); alar cartilages too weak to do so are "inadequately projecting" (Figs. 4, *above, left*, and *below, left*; 5, *below, left*; 7, *center, left*, and *below, left*; and 8, *center, left*). The value of this definition is that it defines treatment: adequately projecting tips do not need increased projection, but inadequately projecting tips do. In addition, by defining tip projection relative to the septal angle, the surgeon can distinguish between two associated but distinct entities: (1) the intrinsic anterior supporting strength supplied by the alar cartilages and (2) skin sleeve volume and distribution in the lower nasal third.

An inadequately projecting tip often appears to "hang" from the septal angle (Figs. 4, *below, left*, and 7, *center, left*, and *below, left*). The amount of *apparent* preoperative tip projection is in fact often partially dependent upon bridge and septal angle height; consequently, as the surgeon reduces the bridge, tip projection also decreases.^{16,59} The surgeon who fails to recognize inadequate tip projection can consequently be swept into a vicious cycle of reducing the bridge more and more, believing that enough dorsal resection will ultimately reveal an adequately projecting tip. This was apparently the case in 80 percent of the secondary patients in this study. Eventually, the combination of bridge reduction and the tip reduction that accompanies it creates supratip deformity (from limited skin contractility) (Figs. 8 and 9),^{2,3,16} internal valvular incompetence (from bridge resection)^{8,21,26,42-46} (Figs. 6, 8, and 9), and external valvular incompetence (from lateral crural reduction)¹¹⁻¹³ (Figs. 8 and 9). Where the alar cartilages cannot project the tip lobule to the level of the supratip septum, the surgeon must employ some "tip strengthening" method (sutures, struts, or grafts) to create that support. Inadequate tip projection cannot be rendered adequate by reducing the dorsum.

Interestingly, a review of Joseph's text indicates that he instinctively treated inadequate

tip projection by limiting his bridge resection and deliberately leaving a dorsal convexity.⁶⁰

Alar Cartilage Malposition

After leaving the lateral genua, the alar cartilage lateral crura most commonly parallel the anterior third of the alar rims and then diverge from them at a 30- to 45-degree angle. There is, however, one common and important variation: in some patients, the lateral crura diverge from the rims at a greater degree (Figs. 5, 8, and 9) and may even parallel the anterior septal edge (Fig. 7). This anatomic variation was first recognized by Sheen⁵² as an aesthetic deformity that often produced a round or boxy tip lobule with characteristic "parentheses" on frontal view. Malposition has, however, two ramifications that are not aesthetic. First, the abnormal position of the lateral crura places them at special risk for an intracartilaginous incision,²³ which will transect the cephalically rotated lateral crura instead of splitting the intended cephalic portion. The entire lateral crus may thus be inadvertently removed: the deformity is characteristic (Figs. 6, *above, left* and *center*, 8, *below, left*, and 9, *above, center*). In the current study, 42 percent of the secondary patients had alar and tip deformities directly related to failure to recognize cephalically malpositioned lateral crura. Secondly, the malpositioned lateral crura cannot provide adequate external valvular support. Our previous reports^{11,12} have indicated that approximately 50 percent of patients presenting with airway obstruction at the external nasal valves have alar cartilage malposition. Adequate treatment of cephalic rotation of the lateral crura requires either resection and replacement of the lateral crura²³; relocation of the lateral crura to support the external valves⁵²; or (in cases where the rotated lateral crura do not create aesthetic deformities) supporting the areas of external valvular collapse with autogenous cartilage grafts.^{12,23} Our rhinomanometric measurements have previously indicated that correction of external valvular incompetence approximately doubles nasal airflow in most patients^{11,12}; the current cohort, nearly twice the size of the most recently published study,²⁶ continues to show improvement of similar magnitudes in both primary and secondary rhinoplasty patients (2.5 times for primary patients, 4.0 times for secondary patients).⁵¹

The incidences of low radix, narrow middle vault, inadequate tip projection, and alar cartilage malposition in our primary rhinoplasty group (Tables III and IV) were similar but

lower than in our secondary population, a finding that might be expected when comparing untreated patients to a skewed population of secondary (and therefore, by definition, dissatisfied), rhinoplasty patients. However, whereas 100 percent of the secondary patients had at least one of the four variants before their primary rhinoplasties, only 78 percent of the primary rhinoplasty patients did. The remaining 22 percent, therefore, had proper or high nasal roots, adequate middle vault and nasal tip support, and orthotopic alar cartilages. These are the patients whom one would expect to be treated successfully by traditional reduction rhinoplasty, *provided* that valvular incompetence (at the internal valves from roof resection or at the external valves from excessive lateral crural reduction) is not created inadvertently and adequate tip support is maintained. Assuming that our primary rhinoplasty population follows a Gaussian distribution, however, the number of patients who might be treated successfully by classic reduction rhinoplasty methods alone approximates only 20 percent.

The adverse effects of unrepaired or newly created valvular incompetence following rhinoplasty should not be underestimated. Because treatment of internal or external valvular incompetence approximately doubles airflow^{11,12,26,51} and because treatment of insufficiency at *both* sets of valves increases airflow 3.8 times over preoperative values²⁶ [currently in our long-term group, 4.5 times for primary patients and 2.6 times for secondary patients, $p < 0.009$ (t test for paired samples assuming unequal variances)⁵¹], one might reasonably conjecture that *creation* of valvular incompetence at either or both sets of valves may decrease postoperative airflow 50 to 75 percent below preoperative values. Valvular obstruction is four times more common than septal obstruction in our primary rhinoplasty patients and 12 times more common in our secondary patients.⁵¹ Furthermore, our recent data indicate that the magnitude of airflow improvement for primary rhinoplasty patients equals or exceeds the improvement achieved by secondary patients in six of the seven obstructive sites examined, which challenges the axiom that a decrease in nasal airflow necessarily follows cosmetic rhinoplasty.⁵¹

CONCLUSIONS

This review of 150 consecutive patients on whom I performed secondary rhinoplasty indi-

cates that only four anatomic traits (two or more occurring in 99 percent of the patients) were associated with the unsatisfactory result in each of these individuals. Forty percent of these patients had the triad of low radix, narrow middle vault, and inadequate tip projection; 28 percent had each of the four characteristics; and 78 percent of the patients had three or all four anatomic variants in some combination. Comparable, but lower, incidences existed in my primary patients. However, 78 percent of the primary patients had two or more of the traits, and 58 percent had three or all four. It is important for all surgeons performing rhinoplasty to recognize these anatomic variants preoperatively to avoid the unsatisfactory sequelae that they may produce, either by being conservative in skeletal reduction, or even better, by making their correction a deliberate part of each preoperative surgical plan.

Mark B. Constantian, M.D.
19 Tyler Street
Nashua, N.H. 03060
consmdpa@aol.com

ACKNOWLEDGMENTS

The author gratefully acknowledges the operating room assistance of Dennis Griffin, C.S.T., Susan Demers, R.N., and Jennifer Gagnon, C.R.N.A.; the artwork of Nancy Kaplan, M.S.; the research assistance of Janice Silver, M.A.; and the expert technical assistance of R. Brian Clardy, Olivia Williams Smith, and Charlotte Constantian.

REFERENCES

1. Constantian, M. B. Primary Rhinoplasty. In M. Cohen (Ed.), *Mastery of Plastic and Reconstructive Surgery*. Boston: Little, Brown, 1994. Pp. 1999–2020.
2. Sheen, J. H. A new look at supratip deformity. *Ann. Plast. Surg.* 3: 498, 1979.
3. Sheen, J. H., and Sheen, A. P. *Aesthetic Rhinoplasty*, 2nd Ed. St. Louis: Mosby, 1987. Pp. 1200–1241.
4. Constantian, M. B. The middorsal notch: An intraoperative guide to overresection in secondary rhinoplasty. *Plast. Reconstr. Surg.* 91: 477, 1993.
5. Constantian, M. B. Distant effects of dorsal and tip grafting in rhinoplasty. *Plast. Reconstr. Surg.* 90: 405, 1992.
6. Sheen, J. H., and Constantian, M. B. Primary Rhinoplasty. In J. W. Smith and S. J. Aston (Eds.), *Grabb and Smith's Plastic Surgery*. Boston: Little, Brown, 1991.
7. Sheen, J. H., and Sheen, A. P. *Aesthetic Rhinoplasty*. St. Louis: Mosby, 1987. Pp. 1322–1327.
8. Sheen, J. H., and Sheen, A. P. *Aesthetic Rhinoplasty*. St. Louis: Mosby, 1987. Pp. 1142–1165.
9. Constantian, M. B. An alternate strategy for reducing the large nasal base. *Plast. Reconstr. Surg.* 83: 41, 1989.
10. Sheen, J. H., and Sheen, A. P. *Aesthetic Rhinoplasty*. St. Louis: Mosby, 1987. Pp. 1044–1055.
11. Constantian, M. B. The incompetent external nasal valve: Pathophysiology and treatment in primary and secondary rhinoplasty. *Plast. Reconstr. Surg.* 93: 919, 1994.

12. Constantian, M. B. Functional effects of alar cartilage malposition. *Ann. Plast. Surg.*, 30: 487, 1993.
13. Sheen, J. H., and Sheen, A. P. *Aesthetic Rhinoplasty*, 2nd Ed. St. Louis: Mosby, 1987. Pp. 25–42.
14. Sheen, J. H., and Sheen, A. P. *Aesthetic Rhinoplasty*, 2nd Ed. St. Louis: Mosby, 1987. Pp. 807–1061.
15. Sheen, J. H., and Sheen, A. P. *Aesthetic Rhinoplasty*, 2nd Ed. St. Louis: Mosby, 1987. Pp. 808–826.
16. Sheen, J. H., and Sheen, A. P. *Aesthetic Rhinoplasty*, 2nd Ed. St. Louis: Mosby, 1987. Pp. 946–962.
17. Hamra, S. T. Crushed cartilage grafts over alar dome reduction in open rhinoplasty. *Plast. Reconstr. Surg.* 92: 352, 1993.
18. Adham, M. N., and Teimourian, B. Treatment of alar cartilage malposition using cartilage disc graft technique. *Plast. Reconstr. Surg.* (in press).
19. Constantian, M. B. Treatment of alar cartilage malposition using cartilage disc graft technique (Discussion). *Plast. Reconstr. Surg.* (in press).
20. Sheen, J. H., and Sheen, A. P. *Aesthetic Rhinoplasty*, 2nd Ed. St. Louis: Mosby, 1987. Pp. 828–863.
21. Sheen, J. H. Spreader graft: A method of reconstructing the roof of the middle nasal vault following rhinoplasty. *Plast. Reconstr. Surg.* 73: 230, 1984.
22. Sheen, J. H. Achieving more nasal tip projection by the use of a small autogenous vomer or septal cartilage graft: A preliminary report. *Plast. Reconstr. Surg.* 56: 35, 1975.
23. Sheen, J. H., and Sheen, A. P. *Aesthetic Rhinoplasty*, 2nd Ed. St. Louis: Mosby, 1987. Pp. 988–1011.
24. Sheen, J. H., and Sheen, A. P. *Aesthetic Rhinoplasty*, 2nd Ed. St. Louis: Mosby, 1987.
25. Constantian, M. B. Elaboration of an alternative, segmental, cartilage-sparing tip graft technique: Experience in 405 cases. *Plast. Reconstr. Surg.* 103: 237, 1999.
26. Constantian, M. B., and Clardy, R. B. The relative importance of septal and nasal valvular surgery in correcting airway obstruction in primary and secondary rhinoplasty. *Plast. Reconstr. Surg.* 98: 38, 1996.
27. Sheen, J. H., and Sheen, A. P. *Aesthetic Rhinoplasty*, 2nd Ed. St. Louis: Mosby, 1987. Pp. 1135–1408.
28. Peck, G. C. *Techniques in Aesthetic Rhinoplasty*. Philadelphia: Lippincott, 1990. Pp. 137, 190.
29. Gunter, J. P., and Rohrich, R. J. External approach for secondary rhinoplasty. *Plast. Reconstr. Surg.* 80: 161, 1987.
30. McKinney, P., and Cunningham, B. L. *Rhinoplasty*. New York: Churchill-Livingstone, 1989.
31. Aiach, G., and Levignac, J. *La Rhinoplastie Esthetique*. Paris: Masson, 1989. Pp. 84–90.
32. Daniel, R. K. Secondary rhinoplasty following open rhinoplasty. *Plast. Reconstr. Surg.* 96: 1539, 1995.
33. Johnson, C. M., and Toriumi, D. M. Open structure rhinoplasty: Featured technical points and long term followup. *Facial Plast. Surg. Clin. North Am.* 1: 1, 1993.
34. Tebbetts, J. B. Shaping and positioning the nasal tip without structural disruption: A new, systematic approach. *Plast. Reconstr. Surg.* 94: 61, 1994.
35. Tardy, M. E., Jr., Patt, B. S., and Walter, M. A. Transdomal suture refinement of the nasal tip: Long-term outcomes. *Facial Plast. Surg.* 9: 275, 1993.
36. Hoefflin, S. M. Geometric sculpturing of the thick nasal tip. *Aesthetic Plast. Surg.* 18: 247, 1994.
37. Gruber, R. P., and Friedman, G. Secondary Rhinoplasty (Open Approach). In R. P. Gruber and G. C. Peck (Eds.), *Rhinoplasty: State of the Art*. St. Louis: Mosby, 1993. Pp. 237–254.
38. Millard, D. R. *A Rhinoplasty Tetralogy: Corrective, Secondary, Congenital, Reconstructive*. Boston: Little, Brown, 1996. Pp. 119–210.
39. Daniel, R. K. Rhinoplasty: A simplified, three-stitch, open tip suture technique. Part II: Secondary rhinoplasty. *Plast. Reconstr. Surg.* 103: 1503, 1999.
40. Aiach, G., and Monaghan, P. Treatment of over-reduction of the nose and subsequent deformities. *Br. J. Oral Maxillofac. Surg.* 33: 250, 1995.
41. Rohrich, R. J., Sheen, J. H., Burget, G. C., and Burget, D. E. *Secondary Rhinoplasty and Nasal Reconstruction*. St. Louis: Quality Medical Publishing, 1996.
42. Sheen, J. H., and Sheen, A. P. *Aesthetic Rhinoplasty*, 2nd Ed. St. Louis: Mosby, 1987. Pp. 766–771.
43. Sheen, J. H. *Aesthetic Rhinoplasty*. St. Louis: Mosby, 1978. Pp. 310–346.
44. Teichgraeber, J. F., and Wainwright, D. J. The treatment of nasal valve obstruction. *Plast. Reconstr. Surg.* 93: 1174, 1994.
45. Rohrich, R. J., and Hollier, L. H. Rhinoplasty: Dorsal Reduction and Spreader Grafts. In J. P. Gunter and R. J. Rohrich (Eds.), *Dallas Rhinoplasty Symposium Syllabus*, 1997. Pp. 195–208.
46. Teller, D. C. Anatomy of a rhinoplasty: Emphasis on the middle third of the nose. *Facial Plast. Surg.* 13: 241, 1997.
47. Guyuron, B., Michelow, B. J., and Englehardt, C. Upper lateral splay graft. *Plast. Reconstr. Surg.* 102: 2169, 1998.
48. Fomon, S., Gilbert, J. G., Caron, A. L., and Segal, S., Jr. Collapsed ala: Pathologic physiology and management. *Arch. Otolaryngol.* 51: 465, 1950.
49. Kern, E. B. Evaluation of Nasal Breathing: An Objective Method. In T. D. Rees (Ed.), *Rhinoplasty: Problems and Controversies*. St. Louis: Mosby, 1986. Pp. 195–202.
50. Sulsenti, G., and Palma, P. A new technique for functional surgery of the nasal valve area. *Rhinology* 10 (Suppl.): 1, 1989.
51. Constantian, M. B. Further Observations on the Effect of Valvular and Septal Reconstruction in 105 Consecutive Long-Term Rhinoplasty Patients. Presented at the Annual Meeting of the Rhinoplasty Society, Los Angeles, Calif., May 1998.
52. Sheen, J. H. *Aesthetic Rhinoplasty*. St. Louis: Mosby, 1978. Pp. 432–462.
53. Petroff, M. A., McCollough, E. G., Hom, D., and Anderson, J. R. Nasal tip projection: Quantitative changes following rhinoplasty. *Arch. Otolaryngol. Head Neck Surg.* 117: 783, 1991.
54. Ricketts, R. M. Divine proportion in facial esthetics. *Clin. Plast. Surg.* 9: 401, 1982.
55. Gunter, J. P. Facial Analysis for the Rhinoplasty Patient. In J. P. Gunter and R. J. Rohrich (Eds.), *Dallas Rhinoplasty Symposium Syllabus*, 1997. Pp. 195–208.
56. Daniel, R. K. Nasal Analysis and Operative Planning. In J. P. Gunter and R. J. Rohrich (Eds.), *Dallas Rhinoplasty Symposium Syllabus*, 1997. Pp. 35–44.
57. Papell, I. D., and Mabrie, D. C. Deprojecting the nasal profile. *Otolaryngol. Clin. North Am.* 32: 65, 1999.
58. Constantian, M. B. A model for planning rhinoplasty. *Plast. Reconstr. Surg.* 79: 472, 1987.
59. Constantian, M. B. The septal angle: A cardinal point in rhinoplasty. *Plast. Reconstr. Surg.* 85: 187, 1990.
60. Joseph, J. *Nasenplastik und Sonstige Gesichtsplastik*. Leipzig: Verlag, 1931. Pp. 94, 98, 166.
61. Sheen, J. H., and Sheen, A. P. *Aesthetic Rhinoplasty*, 2nd Ed. St. Louis: Mosby, 1987. Pp. 453–461.